

Video as an interventional tool for bridging the gap in anatomy knowledge of medical postgraduates

Anatomy
knowledge of
medical
postgraduates

Pamela David

Universiti Malaya, Kuala Lumpur, Malaysia

Intan S. Zulkafli, Rasheeda Mohd Zamin, Snehlata Samberkar and
Kah Hui Wong

Department of Anatomy, Universiti Malaya, Kuala Lumpur, Malaysia

Murali Naidu

Universiti Malaya, Kuala Lumpur, Malaysia, and

Srijit Das

College of Medicine and Health Sciences, Sultan Qaboos University, Muscat, Oman

Received 6 March 2023

Revised 4 July 2023

6 October 2023

Accepted 12 November 2023

Abstract

Purpose – The teaching and learning of anatomy has experienced a significant paradigm shift. The present study assessed the level of knowledge in anatomy in medical postgraduate students and explored the impact of interventions in the form of anatomical videos on knowledge obtained. An awareness of the importance of human anatomy for clinical skills was created to ensure a certain level of competence be achieved by the end of the anatomy course.

Design/methodology/approach – Postgraduate medical students were recruited from various specialties on voluntary basis. The first step was to conduct a preliminary screening exam to determine the level of anatomical knowledge. The students were then divided into two groups at random, one of which received no intervention (the control group), and the other of which watched the videos with content that was pertinent to the practical demonstrations (intervention). To assess the effects of the video intervention, a post-test was administered to all students.

Findings – Both spot tests (SPOTs) and short answer question (SAQ) components for scores of all the regions from the intervention groups were comparable to the scores obtained by the post-test control group, although the findings were not significant ($p > 0.05$). However, the intervention group from the abdomen (ABD) region did perform significantly better ($p < 0.05$) than the screening test score.

Originality/value – The results of the research study imply that interventions like anatomical videos can bridge the postgraduate trainee's anatomy knowledge gap in a practical method which will immensely help in increasing their knowledge.

Keywords Postgraduate, Anatomy, Videos, Medical education, Anatomy curriculum

Paper type Research paper

© Pamela David, Intan S. Zulkafli, Rasheeda Mohd Zamin, Snehlata Samberkar, Kah Hui Wong, Murali Naidu and Srijit Das. Published in *Arab Gulf Journal of Scientific Research*. Published by Emerald Publishing Limited. This article is published under the Creative Commons Attribution (CC BY 4.0) licence. Anyone may reproduce, distribute, translate and create derivative works of this article (for both commercial and non-commercial purposes), subject to full attribution to the original publication and authors. The full terms of this licence may be seen at <http://creativecommons.org/licences/by/4.0/legalcode>

The authors wish to thank Universiti Malaya-Learning Improvement and Teaching Enhancement Research (UM-LiTeR), Grant (RU002C-2016), for supporting and funding this study [Fund number UM.0000298/HRU.OP]. Authors would also like to thank all the first-year clinical postgraduate students for their contribution and participation.



Arab Gulf Journal of Scientific
Research
Emerald Publishing Limited
e-ISSN: 2536-0051
p-ISSN: 1985-9899

DOI 10.1108/AGJSR-03-2023-0097

1. Introduction

The discipline of gross anatomy is included in the first undergraduate year of a medical curriculum, and it is considered an important element of medical education (Sbayeh, 2016). Unfortunately, by the time postgraduate residency programmes are started, the retention of anatomical knowledge obtained at undergraduate levels becomes suboptimal (Yammine, 2014). Sound knowledge of anatomy is the fundamental basis for all other disciplines in medicine. An earlier study reported the fact that anatomy is the most essential subject for practice in the clinical field (Singh, Yadav, Pandey, & Jones, 2022). Continuous learning should be advocated, and these can be done through many platforms such as YouTube, where short and relevant videos can be accessed quickly to revise any topic in Anatomy.

Residency programmes in the United States have reported the importance of gross anatomy in mastering the discipline and ranked it as the most important subject in basic science (Cottam, 1999). Approximately, 60% of residency programmes felt the need for a refresher course in gross anatomy, and 14% admitted that they were seriously lacking (Cottam, 1999). The Department of Radiation Oncology at Duke University Medical Center designed a 2-year “oncoanatomy” curriculum that included a cadaveric laboratory and found that it immensely helped in broadening their clinical understanding (Cabrera *et al.*, 2011). A study conducted by Chhabra *et al.* (2021) demonstrated the clinical benefits obtained by anaesthesia residents when anatomy was integrated into their postgraduate training.

Traditionally, cadaver dissection has been used to teach gross anatomy. However, curricula involving anatomy have undergone a large paradigm shift. Most curricula no longer offer any cadaveric dissection due to factors such as a reduction in contact hours and lack of resources to obtain cadavers. These factors mandated many medical school curricula to move towards the integration of disciplines (Smith, Freeman, Heylings, Finn, & Davies, 2022; Singh, & Kharb, 2013). Although the contact hours are reduced, anatomical facts are simply irreducible. Students struggle to find ways to memorize structural facts within a limited amount of time. Replacement of traditional teaching with newer student-centred modalities such as team-based learning (Yan *et al.*, 2018), technology-based augmented reality and virtual reality (Heather, Chinnah, & Devaraj, 2019), has helped replace the great reduction in anatomy teaching hours. The availability of fresh human cadavers and reduced numbers of well-trained dissectors are also among various other contributory factors.

In recent years, there has been much concern regarding the decline in the standards of a medical practitioner’s anatomy knowledge, which is lamentable and grossly evidenced in clinical settings (Leveritt, McKnight, Edwards, Pratten, & Merrick, 2016). Hence, it is necessary that core knowledge of anatomy be assimilated by all medical practitioners in order to communicate, treat and practice safely.

Bohl and Gest (2011) studied the effects of a reduction in the gross anatomy curriculum on residents’ perceptions of their clinical preparedness. The respondents in the study really appreciated the elective anatomy course offered to them.

The postgraduate medical training programme at the Universiti Malaya is designed to produce a physician who is considered a professional and a specialist in the domain of general medicine as well as a particular specialty such as surgery, orthopedic surgery, otorhinolaryngology, ophthalmology and rehabilitation medicine. The first stage of the programme comprises basic clinical training in basic medical sciences. Here, postgraduate students undergo coursework involving various disciplines, including anatomy, where they revisit the disciplines taken during the undergraduate basic clinical sciences module. Subsequent stages will incorporate research projects and advanced training in the chosen specialty. Assessments are carried out at various stages of the four-year postgraduate programme.

Regarding the discipline of anatomy, postgraduate students attend a series of overview lectures and demonstrations mainly to recall anatomy knowledge acquired during their

undergraduate training, and hence strengthen their concepts in clinical/applied anatomy. Surprisingly, only a few of the postgraduate students had excellent recall of factual anatomy a large number had very little recall of anatomical knowledge, and a few were frighteningly deficient. If these students anatomy knowledge is inadequate, they may not be able to pass or complete their four-year of clinical master's programme.

Therefore, the present study aimed to (1) assess the recall of anatomical knowledge in the postgraduate students, (2) create awareness in individuals who are seriously lagging and (3) help them identify ways to acquire adequate knowledge in anatomy in view of ensuring a certain level of competency is achieved during their postgraduate training. The specific objective of this study was to assess the feasibility of incorporating multimedia formatted videos as a tool of intervention to achieve the aforementioned aims. Believing that video intervention can enhance the recall and learning of a subject matter, we hypothesized that the postgraduate students would benefit from watching the video clips presented and deem it a valuable, cost-effective tool to promote efficacy.

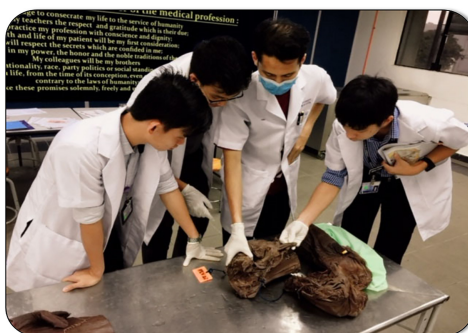2. Materials and methods

2.1 Ethical approval

Participation and sampling were carried out at the beginning of stage 1 of postgraduate study on a voluntary basis. There was no bias for sex, age or type of training received in their undergraduate medical school. This study was reviewed and approved by the Universiti Malaya Research Ethics Committee (UMREC) (UM.TNC2/RC/H&E/UMREC – 129).

2.2 Study design

The first part of the questionnaire comprised the student's demographic details, including the type of undergraduate medical training, they had obtained. This was followed by a preliminary screening test related to the anatomical regions their lecture was based on. The screening test comprised two components, (1) an eight-item SPOTs test where unlabelled anatomical structures needed to be identified as they were projected as slide shows, and (2) one short answer question (SAQ) where a descriptive type of answer was needed. The screening test took no more than 15 mins, and the format was the same for all four regions tested, followed by the usual didactic one-hour lecture. After attending the lectures, the students proceeded to the dissection hall and participated in demonstrations that mainly utilized cadavers and plastinated specimens, along with models and preserved-potted specimens. The demonstration process, as depicted in [Plate 1](#), was facilitated by the respective anatomical region-specific lecturers. Four regions were sampled for the study: the



Source(s): Figure by authors

Plate 1.
Students observing
structures in a hemi-
prosected specimen
during a practical
demonstration

upper limb (UL), abdomen (ABD), pelvis and perineum (P&P) and neck (NECK). The group size (n) for the screening test was as follows: UL = 49, ABD = 51, P&P = 38 and NECK = 47. The group size (n) for the post-test assessment for all regions was 31, as they were conducted on the same day, four weeks later.

Following the demonstration, students were grouped into either a control or an intervention group. The control group of students continued studying on their own, while the intervention group of students were sent to an adjacent tutorial room where they watched video clips (Plate 2) that were deemed useful in enhancing the knowledge acquired via the lecture and demonstrations held earlier. The videos were mainly taken from YouTube and supplemented with Acland's Video Atlas of Human Anatomy. The chosen video clips acted as an adjunct to dissections and contained relevant surgical procedures and clinical anatomy highlights.

Once all the regions were completed in a time frame of four weeks, assessments were carried out to test their knowledge. The post-test assessments comprised SPOTs, SAQs and open-ended questions regarding their perceptions of the course conducted in the four weeks of their study.

2.3 Statistical analysis

All screening tests and post-tests were examined by four lecturers in the department of Anatomy. The data were presented as mean/average percentages \pm SEM. Statistical analysis was performed with a one-way or two-way analysis of variance (ANOVA) and student's *T*-test comparing both control and intervention groups using GraphPad Prism 7.0 software (San Diego, CA, USA). The *p* value of less than 0.05 ($p < 0.05$) was considered to be statistically significant. The questionnaires were also evaluated, and qualitative comments were tabulated.

3. Results

The postgraduate students who participated in this study were in the age range of 29–35 years. They obtained their undergraduate medical degree from various institutions in Malaysia (Universiti Malaya, University Kebangsaan Malaysia, Universiti Putra Malaysia, University Sains Malaysia, Asian Institute of Medicine, Science and Technology, Melaka-Manipal Medical College, International Medical University) and abroad (Kasturba Medical college, National University of Ireland Galway, University of Aberdeen, The University of Melbourne, RCSI Dublin, University of Southampton), both government and private sponsored. Students represented general surgery (Gen Surgery), obstetrics and gynaecology

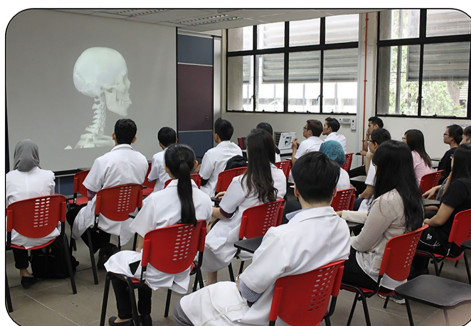

Plate 2.
Students watching
videos (NECK region)
as a tool of intervention

Source(s): Figure by authors

(O&G), Otorhinolaryngology (ENT), internal medicine (IM), orthopaedics (ORTHO), rehabilitation medicine (REHAB), sports medicine (SPORTS MED) and a variety of specialties branching from dentistry (DENTAL) such as oral medicine and oral pathology and prosthodontics.

It is worth mentioning that attendance was not compulsory, and postgraduate students chose to attend what was relevant to their specialty. Few students chose to attend all four regions. Although we did not have any control over the attendance, it was noted that the students attended the demonstrations at the dissection hall, as some claimed not to have the opportunity to study using cadavers in the pre-clinical years and were amazed at the vast collection of cadaveric specimens available in the Department of Anatomy, Universiti Malaya. A total of 51 students participated in this study, and the number of responses varied depending on the specialties of interest of the students who attended. Questionnaires with incomplete responses were excluded.

The results were divided into the following divisions:

- (1) Screening test - to assess the baseline anatomy knowledge of the postgraduate medical students.
- (2) Post-test - to compare the scores between the control and intervention (video) groups.
- (3) Screening test versus post-test - to assess the anatomy knowledge acquired from attending the basic medical science course and to evaluate the performance before and after interventions.

3.1 Screening test

Screening tests carried out in the UL region showed higher scores in the Gen Surgery, SPORTS MED and REHAB groups (Figure 1a). The lowest scores were observed in the O&G specialty.

As shown in Figure 1b, the screening test scheduled during ABD showed the highest score for Gen Surgery (SPOTs component- 93.8%) and lowest for DENTAL (SAQ component- 6.7%). Generally, students scored better in SPOTs compared to SAQs.

The screening tests for the P&P region (Figure 1c) showed that the O&G specialty scored the highest (65.0%) and that was from the SAQ component. Gen Surgery scored highest in the SPOTs component (51.8%), and DENTAL specialty scored lowest for both SPOTs (8.3%) and SAQ (6.0%) components.

Regarding the NECK region (Figure 1d), only 3 specialties participated in the study actively, and ENT scored the highest in both components. Only two students from REHAB and one from ORTHO were present, and they did not complete the screening test. Therefore, the results were not included.

Overall, most specialties scored better for SPOTs compared to SAQs.

3.2 Post-test scores

Both SPOTs and SAQ component scores for all regions from the intervention groups were better than the scores obtained by the control group, although the findings are not significant ($p > 0.05$) (Figure 2).

We further analysed the post-test scores between different specialties, as shown in Figure 3. For UL, the ORTHO group scored the highest (76.2% and 81.0% for the control and intervention groups, respectively). The Gen Surgery and ENT groups passed, but the DENTAL group scored 22.2% (control) and 33.3% (intervention). Regarding the abdominal region, Gen Surgery and ORTHO students scored well, that is, Gen Surgery: 78.2% (control) and 83.8% (intervention); ORTHO: 57.1% (control) and 80.0% (intervention), but the

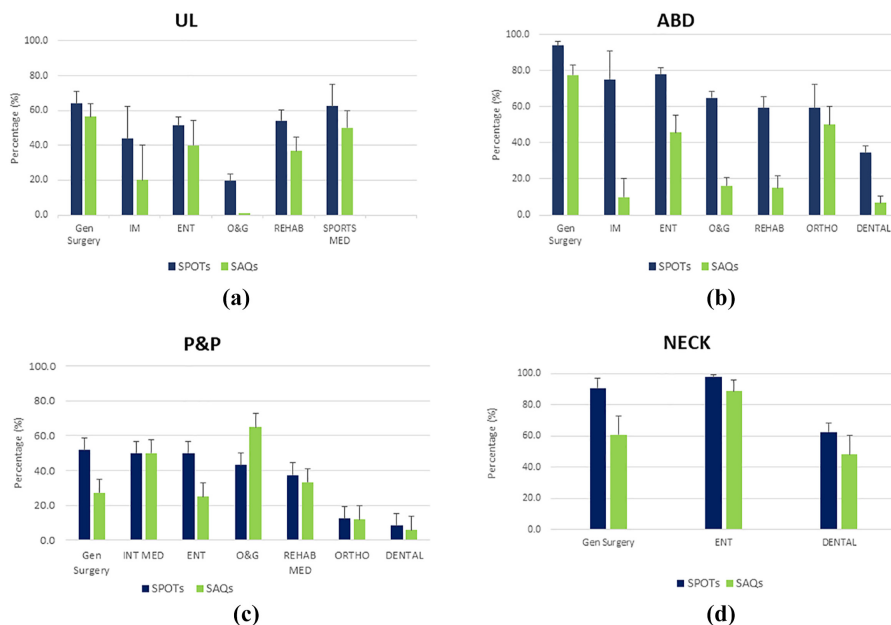
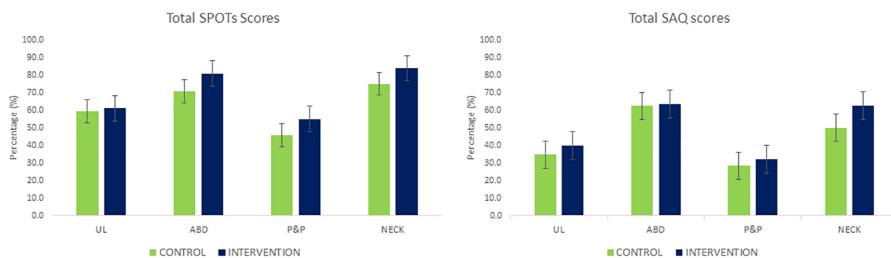


Figure 1. Screening test scores for SPOTs and SAQs according to different anatomy regions: (a) UL, (b) ABD, (c) P&P and (d) NECK

Note(s): UL: upper limb; ABD: abdomen; P&P: pelvis and perineum; NECK: neck; Gen Surgery: General surgery; IM: internal medicine; ENT: otorhinolaryngology; O&G: obstetrics & gynaecology; REHAB: rehabilitation medicine; SPORTS MED: sports medicine; DENTAL: dentistry; SPOTs: Spot tests, SAQ: short answer question

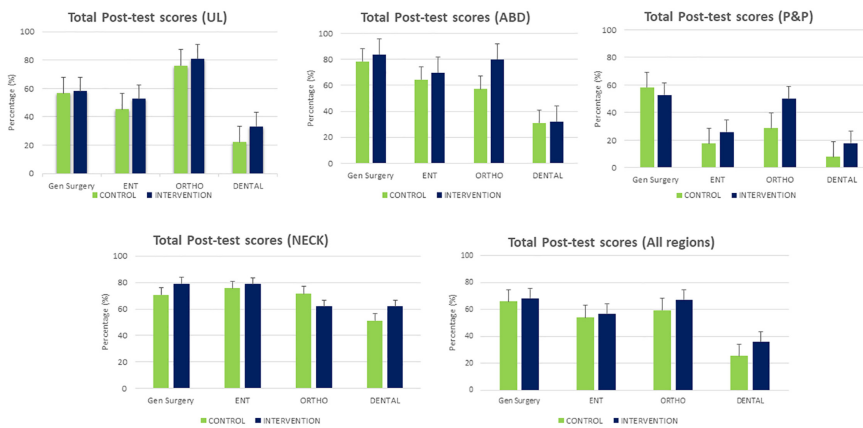
Source(s): Figure by authors

Figure 2. Post-test scores of students from control and intervention groups for all anatomy regions



Source(s): Figure by authors

DENTAL group did not pass as they obtained only 31.0% (control) and 32.1% (intervention). Regarding the P&P region, only the Gen Surgery (58.3% and 52.8% for the control and intervention groups, respectively), and the intervention group from ORTHO (50.0%) passed. All of the ENT, DENTAL and control groups from ORTHO scored below 30.0%. Interestingly, all groups passed the post-test for the NECK region (average of 51.1% to 79.0%), and the control group from ORTHO did perform better (71.4%) than the intervention group (61.9%). Cumulatively, the Gen Surgery, ENT and ORTHO groups passed the post-test for all regions, but DENTAL students performed significantly ($p < 0.05$) below average (28.3% and 36.3% for the control and intervention groups, respectively).



Note(s): UL: upper limb; ABD: abdomen; P&P: pelvis and perineum; NECK: neck; Gen Surgery: General surgery; IM: internal medicine; ENT: otorhinolaryngology; O&G: obstetrics & gynaecology; REHAB: rehabilitation medicine; SPORTS MED: sports medicine; DENTAL: dentistry; SPOTs: Spot tests, SAQ: short answer question
Source(s): Figure by authors

Figure 3.
Post-test scores for
different specialities

3.3 Screening test versus post-test scores

Regarding [Figure 4\(a\)](#), for the UL region, the average score for the intervention group was the highest (61% SPOTs component), and the SAQ scores were below 50% for all three screening tests, post-test control and intervention groups. On the other hand, for ABD ([Figure 4b](#)), the

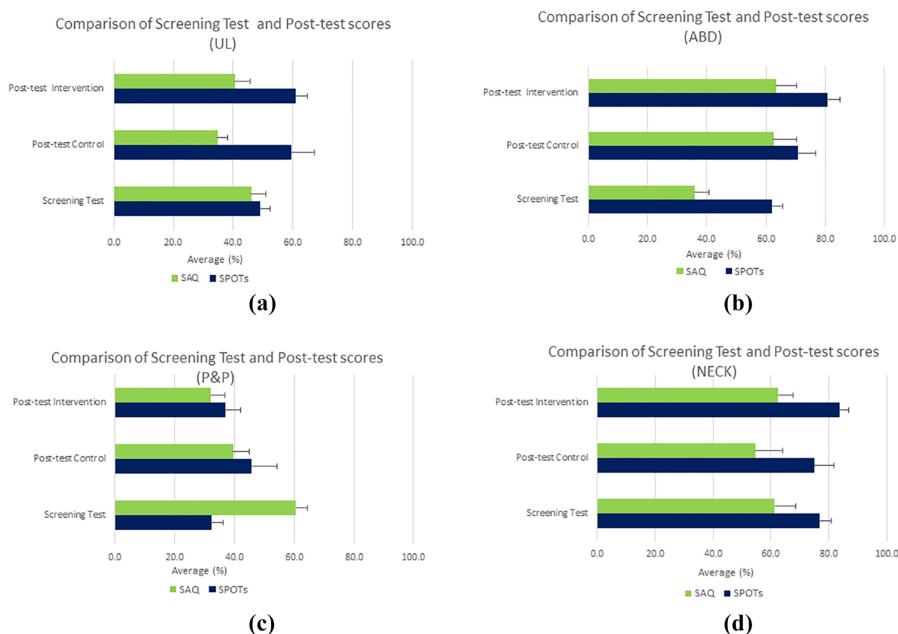


Figure 4.
Comparison between
screening test and post-
test scores of all
speciality for (a) UL
region, (b) ABD region,
(c) P&P and (d) NECK
region

Source(s): Figure by authors

average score for the intervention group was highest for both the SPOTs (80.9%) and SAQ (63.4%) components, and screening test scores were significantly lower ($p < 0.05$) for both components, although SPOTs questions scored a good pass (35.9%-SAQ, 62.1%-SPOTs). The average scores for both components were lowest for the P&P region across all test modalities except the SAQ scores from the screening test (60.6%) that were significantly higher (Figure 4c). Also, the scores for the intervention group were lower than those for the control group. For the NECK region, average scores for the intervention group were highest for both SPOTs (84%) and SAQ (63%) components (Figure 4d), although these were non-significant when compared to the screening test scores.

3.4 Undergraduate curricula type and learning modality

The postgraduate students stated that they learnt anatomy either by regions or by systems. The average scores for SPOTs and SAQs were 51.0% and 43.6%, respectively, for students who learnt anatomy by the regions, and the average scores of those who learnt by systems were 44.6% and 45.8%, respectively.

The type of learning modality employed in their undergraduate study includes dissection, prosection, models and a mixture of more than one type of modality with additional online videos. Figure 5 depicts the average scores obtained according to the modality of learning employed. Students with a mixed mode modality seem to score the highest average (54.9%) followed by learning via prosection (50.6%), dissection (41.6%) and models (37.6%).

3.5 Qualitative results

Generally, those who were in the intervention group gave positive feedback, when asked “how do you feel about the video intervention?” Table 1 summarizes a few of the written feedback statements by the postgraduate students.

4. Discussion

Anatomy is often referred to as the “cornerstone” of healthcare education (Balta, Cronin, Cryan, & O’Mahony, 2015). Anatomists have also described anatomy as the “first link in a long chain of events that teach new skills and competencies to tomorrow’s physicians” (Pawlina & Lachman, 2004). Hence, it is important to have sound knowledge of anatomy in order to become competent physicians.

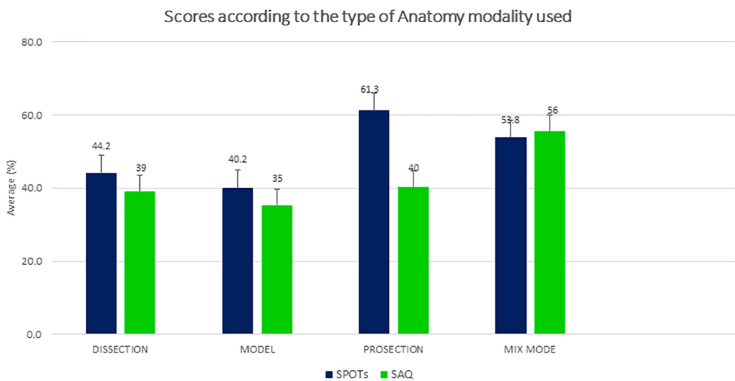


Figure 5. Scores according to the type of learning modality

Source(s): Figure by authors

An inadequate knowledge of anatomy, the inability to properly identify anatomical structures and deficient knowledge of anatomical variations (Kowalczyk & Majewski, 2021) especially at postgraduate levels are alarming handicaps and can result in great medical and surgical errors (Ates *et al.*, 2016). Keeping this in mind, the purpose of the present study was to assess the baseline knowledge of anatomy among the postgraduate students enrolled at the Universiti Malaya, as well as to include a non-invasive intervention that imposes no financial constraints on the learner or the instructor in order to strengthen their knowledge of anatomy as part of their training.

The burden of having to memorize too much structural anatomy during the short training sessions may cause cognitive overload and a loss of interest, resulting in lower performance (Talip, MohdIsmail, & Hadie, 2021; Johnson, 2019). In this regard, a viewpoint has been published regarding the huge volume of work and students who may find it either easy or even difficult to learn anatomy within a short time period (Patel, 2009). An earlier study reported that a decrease in teaching time was associated with inadequate anatomical knowledge needed for safer clinical practice (Singh *et al.*, 2015). Hence, learning anatomy is certainly a daunting task.

The current generation of medical students is technology savvy and frequently uses surgical and clinical videos to gain new knowledge. A past study showed that when e-components were incorporated into a traditionally taught anatomy unit in order to promote teamwork in a large cohort of students from various degree programmes, it proved to be useful (Choudhury & Gouldsbrough, 2012). Although the impact of dissection videos on the academic performance of students remained uncertain, students appreciated them as a resource for learning (Greene, 2020).

Regarding the UL screening test, students were asked to identify bony landmarks (carpal bones, surgical neck of the humerus), and structures such as the brachial artery, median nerve, flexor digitorum superficialis muscle and superficial palmar arch are very region-specific, which may explain the low scores obtained by the O&G group of participants as the focus of attention is region- or discipline-specific. For ABD, when participants had to identify upper gastrointestinal (GIT) structures and blood vessels, the Gen Surgery, IM and ENT students scored significantly better (SPOTs component) than the DENTAL students, and again, a region-specific tendency of knowledge acquisition was seen. SAQ scores were very low for IM, ENT, REHAB and DENTAL participants, and we assume that these students just felt disinclined to participate in writing out short essays, as they may consider that it was just a screening test and not worth the effort. For the P&P region, the pelvic viscera, along with the arterial supply, the pelvic diaphragm and the perineal structures, were tested. It is worth mentioning that as for P&P, it is unknown whether participants from ENT, ORTHO and DENTAL scored significantly lower due to a lack of interest in the region tested in terms of the practical relevance of their specialty or lack of anatomical knowledge in that area.

Question	Comments/suggestions
Which website did you access to help your learning in anatomy?	Acland's Video Atlas of Human Anatomy YouTube
How do you feel about the video intervention?	"Good" "Informative, since I did not have the opportunity to learn using cadavers during my med school" "Good and can be easily retrieved from YouTube" "Helpful and FREE" "(It) make(s) the learning session more interesting" "To have more practical session and longer hours of videos" "Short videos help me pay attention"

Source(s): Table by authors

Table 1.
Summary of the
written feedback
statements by the
postgraduate students

Currently, P&P anatomy is not part of the undergraduate dentistry curriculum. During the NECK screening test, only three (3) specialties (Gen Surgery, ENT and DENTAL) were present, and the average score for ENT was understandably the highest. Here, the neurovascular structures of the neck and deep cervical fascial components were tested.

It may be mentioned that specific challenges are faced by postgraduate students who belong to different disciplines such as Gen Surgery, Orthodontics, O&G and ENT. In Gen Surgery, the challenges faced by these students are understanding intricate anatomical structures and their variations, including surgical application. During their postgraduate course, they need to get hands-on experience operating delicate structures with minimal complications. In order to gain these skills, thorough knowledge of abdominal anatomy is important and can be achieved using cadaveric dissection and video sessions.

The O&G students need comprehensive knowledge of female reproductive anatomy. They face the challenge of understanding the anatomical changes that occur during pregnancy and childbirth. Detailed anatomical knowledge of P&P makes them more skilled in performing gynaecological surgeries and procedures. The ENT students encounter challenges in learning intricate head and neck anatomy, including the complex structures of the ear, nose, throat and related nerves and blood vessels. Detailed anatomical knowledge of the head and neck is crucial for diagnosing and managing conditions related to hearing, balance, smell and vocal function. Hence, in all clinical disciplines, postgraduate students not only need to acquire in-depth knowledge of anatomy but also must apply that knowledge in clinical scenarios, procedures and treatment planning. The challenges faced by the students often include time management, the complexity of anatomical variations and the need for hands-on experience to develop surgical skills or perform clinical examinations. However, with dedication, practice and access to comprehensive learning resources, postgraduates can surely overcome these challenges and excel in their respective fields.

Post-test score analysis revealed that the intervention groups from Gen Surgery, ORTHO and ENT performed significantly better across all regions, whereas the DENTAL group performed significantly lower. Analysing individual regions, the ORTHO group scored significantly ($p < 0.05$) better than other groups in the UL anatomy, while Gen Surgery scored highest for both ABD and P&P anatomy. The intervention group from ORTHO passed the ABD and P&P anatomy, but the DENTAL group did not perform well at all. Again, region-specific and practical skills relevant to the specialty were noted. It was also observed that the ORTHO postgraduate students seemed to have better recall of anatomical knowledge. For the NECK region, all groups had a good pass with an average of 61.9–79.0%. This was probably because the neck is a clinically relevant area for all specialties, and it is a region of the human body that is less complicated as compared to the P&P regions tested here.

The results of the present study showed that although scores from the intervention groups were generally better for the SPOTs components of the UL and P&P, they were non-significant ($p > 0.05$). The scores were also not comparable between the screening group and post-test intervention group for the NECK region, although the intervention group performed better ($p > 0.05$). Only the scores for both SPOTs and SAQ from the ABD region post-test intervention groups were significantly higher ($p < 0.05$) than the screening test scores.

It is worth mentioning that the gross anatomy of the four regions was tested along with clinical applications. Overall, there seemed to be a trend for SPOTs scores to be generally higher than SAQ. This is probably because anatomy is a visual subject, where pictures of anatomical structures are built as three-dimensional images in the mind as the learning occurs, enhancing a quicker memory for identification without the theoretical aspect of having to construct sentences regarding a particular structure. Also, there was no significant difference between learning anatomy by regions or systems.

Postgraduate students were also asked to record the type of learning modality employed in their undergraduate studies. Dissection, prosection, models and a mixture of more than one

type of modality with additional online videos were stated. According to [Figure 5](#), students with mixed modes of learning, scored highest, and students who learnt anatomy using only models scored lowest. Therefore, it is important that, with the curricula involving anatomy teaching ever evolving, institutions try to include more than one mode of teaching anatomy to ensure long-term memory recall of the human body structures.

Although the dissection hall had a wide collection of cadaveric specimens, unfortunately, sufficient fresh cadavers with intact and accurately observable structures, such as blood vessels and nerves, were lacking. Therefore, students regarded the video intervention as informative, which helped them recall anatomical facts in a less stressful way, and they were able to engage with the content. Approximately, 81% of students reported having used YouTube videos to assist them with learning anatomy. Few students (7%) used Acland's Video Atlas of Human Anatomy. Meanwhile, a few participants admitted to having no access to additional online resources to aid their undergraduate learning of anatomy. Using videos to enhance learning has many benefits, such as a great increase in understanding of experimental principles in view of performing certain techniques ([Lacey & Wall, 2021](#)), accelerated learning and improved performance ([Hansen *et al.*, 2011](#); [Mehrpour, Aghamirsalim, Motamedi, ArdeshtirLarijani, & Sorbi, 2013](#)). An earlier study involving 13 otolaryngology residents rated the videos shown as useful and admitted their ability to promote self-efficacy, as well as serve as a surgical preparation tool ([Poon, Stevens, Golub, Pensak, & Samy, 2017](#)). There are various ways of teaching anatomy, and these include anatomical models, plastinated materials, computer-aided learning, radio anatomical screening, virtual models and different complementary strategies ([Bacro, Gebregziabher, & Ariail, 2013](#); [Canty, Hayes, Story, & Royse, 2015](#); [Kotze' *et al.*, 2013](#); [McNulty, Sonntag, & Sinacore, 2009](#); [Stirling & Birt, 2014](#)). During recent years, there is an upsurge in video streaming, web-based computer-aided learning and active use of the Moodle platform that helps in better teaching of anatomy ([McNulty *et al.*, 2009](#); [Saxena, Natarajan, O'Sullivan, & Jain, 2008](#)). Published research depicts that a large number of students who utilized and incorporated the videos as preparatory learning benefitted in terms of knowledge ([Granger *et al.*, 2007](#); [Nance, Lanning, & Gunsolley, 2009](#)). It was found that the students obtained the information both visually and verbally, and the digital optical data and online material helped the students gain access to quality learning material ([Stirling & Birt, 2014](#); [Sutkin, Littleton, & Kanter, 2015](#)). Videos are also helpful in teaching a large number of students, and an earlier published article reported this ([Stirling & Birt, 2014](#)). The advantages of having video-assisted learning are that the students can use their own time and at their own pace ([Pawlina & Lachman, 2004](#)). It was reported that online demonstrations helped the students remember vital information with proper utilization of time and easy access to the content at their own speed with much flexibility ([Potu *et al.*, 2022](#)). Technology-based video-assisted learning can even be beneficial in reaching students at a far distance.

Finally, since the postgraduate basic science course is short, lectures comprise an overview of regional anatomy, and therefore, it is desirable that additional detail be obtained through supplementary modes of learning, which include video intervention. Other modes of supplementation include reading electronic books with schematics and mnemonics ([Chung *et al.*, 2020](#)), using digital learning tools such as software to browse serial medical images ([Kwon, Chung, Park, Shin, & Chung, 2017](#)), portable document format files showing surface models of cadavers ([Shin *et al.*, 2012](#)) and flipped classroom pedagogy ([Fleagle, Borcharding, Harris, & Hoffmann, 2018](#)). The results of the present study support many practical implications of anatomy teaching. Virtual and augmented reality devices ([Moro *et al.*, 2021](#)) and tablet-based applications were shown to promote intrinsic benefits like increased learner engagement. According to the earlier research studies, 3D and virtual technology offer students accessible, affordable solutions for anatomy instruction without compromising with the quality of their learning chances ([Zargaran, Turki, Bhaskar, Spiers, & Zargaran, 2020](#)). It is possible to

personalize 3D and virtual technology, which could be a useful addition to self-directed learning and complement the conventional classroom teaching strategies. (Tworek, Jamniczky, Jacob, Hallgrímsson, & Wright, 2013; Li, Ran, Zhang, Tan, & Qiu, 2014). An innovative and a new web-based learning tool “Radstax” for radiological anatomy was tested, and it was found that 87% of the students found it to be highly effective compared to the existing methods of teaching at undergraduate level (Colucci *et al.*, 2015). Interestingly, a study conducted on 91 second-year medical students found that 98% of them used YouTube and online resources for learning, and this paved the way for creating a “Human Anatomy Education Channel” (Jaffar *et al.*, 2012). A study conducted in Sydney, which integrated ultrasound imaging in abdominal anatomy teaching, showed that 76–80% of the students found it to be a good supplementation to cadavers (Moscova, Bryce, Sindhusake, & Young, 2015). A two-year study was conducted on medical students, and the results showed that students felt more comfortable with imaging tools, and it helped them a lot in identification of various anatomical structures (Swamy & Searle, 2012). Another important advantage of including imaging technology in anatomy lessons is that it helps prepare students for future interactions with imaging investigations in future clinical setup (Zargaran *et al.*, 2020). However, these electronic learning tools can be costly, and many institutions may not have adequate budget allocations to afford them.

Admittedly, the present study had a few limitations. The most notable one was the number of participants that varied across the four regions sampled. This was partly due to poor attendance for classes during the basic science course, as attendance was not compulsory; most of these students left their homes, travelled interstate and took time off to come to Universiti Malaya to complete this component of their course. Secondly, the basic science course was only carried out for two (2) weeks in July and two (2) weeks in September. The scheduled slots were quite limited, and that did not permit the anatomy lecturers much room to explore our intervention any longer than given. Nevertheless, it will be extremely beneficial if the anatomy teaching and learning can be improved at the basic medical sciences component, since it is evident from the screening test that the knowledge retained seems inadequate. This study also demonstrated that specialties that did not perform sufficiently well could seek separate anatomy courses that could help them acquire the baseline anatomical knowledge needed for safe practice.

5. Conclusion

In the present study, additional video intervention was added to enhance clinical postgraduate students' knowledge of anatomy. The implications of the study highlight the fact that the anatomical videos can fill the gaps in the structural facts, and this was clearly seen in the performance of the post-test assessment. Hence, in the future, anatomy videos could be included as a component of teaching in the undergraduate curriculum. As the postgraduate students have very limited time to refresh and improve their proficiency in anatomical knowledge during the basic science course, video intervention showed a great potential to enhance their knowledge, and students have the liberty to access the videos at any time and at their own convenience. The anatomy videos could be used for teaching and assessment of the postgraduates during their clinical tenure. Future research studies are warranted in this aspect. Overall, video intervention is greatly encouraged as we are moving towards a blended learning environment, and a follow-up study can be planned to further explore ways and mechanisms to instil the needed knowledge in anatomy. This may help in producing better clinicians.

References

- Ates, M., Kinaci, E., Kose, E., Soyer, V., Sarici, B., Cuglan, S., . . . Dirican, A. (2016). Corona mortis: In vivo anatomical knowledge and the risk of injury in totally extraperitoneal inguinal hernia repair. *Hernia: The Journal of Hernias and Abdominal Wall Surgery*, 20(5), 659–665. doi: 10.1007/s10029-015-1444-8.

-
- Bacro, T. R., Gebregziabher, M., & Ariail, J. (2013). Lecture recording system in anatomy: Possible benefit to auditory learners. *Anatomical Sciences Education*, 6(6), 376–384. doi: [10.1002/ase.1351](https://doi.org/10.1002/ase.1351).
- Balta, J. Y., Cronin, M., Cryan, J. F., & O'Mahony, S. M. (2015). Human preservation techniques in anatomy: A 21st century medical education perspective. *Clinical Anatomy (New York, N.Y.)*, 28(6), 725–734. doi: [10.1002/ca.22585](https://doi.org/10.1002/ca.22585).
- Bohl, M. A., & Gest, T. R. (2011). Resident perceptions of anatomy education: A survey of medical school alumni from two different anatomy curricula and multiple medical specialties. *Anatomical Sciences Education*, 4(3), 126–131. doi: [10.1002/ase.207](https://doi.org/10.1002/ase.207).
- Cabrera, A. R., Lee, W. R., Madden, R., Sims, E., Hoang, J. K., White, L. E., . . . Chino, J. P. (2011). Incorporating gross anatomy education into radiation oncology residency: A 2-year curriculum with evaluation of resident satisfaction. *Journal of the American College of Radiology : JACR*, 8(5), 335–340. doi: [10.1016/j.jacr.2010.10.005](https://doi.org/10.1016/j.jacr.2010.10.005).
- Canty, D. J., Hayes, J. A., Story, D. A., & Royse, C. F. (2015). Ultrasound simulator-assisted teaching of cardiac anatomy to preclinical anatomy students: A pilot randomized trial of a three-hour learning exposure. *Anatomical Sciences Education*, 8(1), 21–30. doi: [10.1002/ase.1452](https://doi.org/10.1002/ase.1452).
- Chhabra, S., Mohammed, S., Bhatia, P., Ghatak, S., Paliwal, B., & Soni, P. (2021). Vertical integration in postgraduate teaching for anaesthesiology residents: A questionnaire based descriptive cross-sectional study. *Medical Journal, Armed Forces India*, 77(Suppl 1), S220–S226. doi: [10.1016/j.mjafi.2021.01.003](https://doi.org/10.1016/j.mjafi.2021.01.003).
- Choudhury, B., & Gouldsborough, I. (2012). The use of electronic media to develop transferable skills in science students studying anatomy. *Anatomical Sciences Education*, 5(3), 125–131. doi: [10.1002/ase.1259](https://doi.org/10.1002/ase.1259).
- Chung, B. S., Koh, K. S., Oh, C. S., Park, J. S., Lee, J. H., & Chung, M. S. (2020). Effects of reading a free electronic book on regional anatomy with schematics and mnemonics on student learning. *Journal of Korean Medical Science*, 35(6), e42. doi: [10.3346/jkms.2020.35.e42](https://doi.org/10.3346/jkms.2020.35.e42).
- Colucci, P. G., Kostandy, P., Shrauner, W. R., Arleo, E., Fuortes, M., Griffin, A. S., . . . Tsiouris, A. J. (2015). Development and utilization of a web-based application as a robust radiology teaching tool (radstax) for medical student anatomy teaching. *Academic Radiology*, 22(2), 247–255. doi: [10.1016/j.acra.2014.09.014](https://doi.org/10.1016/j.acra.2014.09.014).
- Cottam, W. W. (1999). Adequacy of medical school gross anatomy education as perceived by certain postgraduate residency programs and anatomy course directors. *Clinical Anatomy (New York, N.Y.)*, 12(1), 55–65. doi: [10.1002/\(SICI\)1098-2353\(1999\)12:1<55::CO;2-O>3.0.CO;2-O](https://doi.org/10.1002/(SICI)1098-2353(1999)12:1<55::CO;2-O>3.0.CO;2-O).
- Fleagle, T. R., Borcharding, N. C., Harris, J., & Hoffmann, D. S. (2018). Application of flipped classroom pedagogy to the human gross anatomy laboratory: Student preferences and learning outcomes. *Anatomical Sciences Education*, 11(4), 385–396. doi: [10.1002/ase.1755](https://doi.org/10.1002/ase.1755).
- Granger, N. A., & Calleson, D. (2007). The impact of alternating dissection on student performance in a medical anatomy course: Are dissection videos an effective substitute for actual dissection?. *Clinical Anatomy (New York, N.Y.)*, 20(3), 315–321. doi: [10.1002/ca.20359](https://doi.org/10.1002/ca.20359).
- Greene, S. J. (2020). The use of anatomical dissection videos in medical education. *Anatomical Sciences Education*, 13(1), 48–58. doi: [10.1002/ase.1860](https://doi.org/10.1002/ase.1860).
- Hansen, M., Oosthuizen, G., Windsor, J., Doherty, I., Greig, S., McHardy, K., & McCann, L. (2011). Enhancement of medical interns' levels of clinical skills competence and self-confidence levels via video iPods: Pilot randomized controlled trial. *Journal of Medical Internet Research*, 13(1), e29. doi: [10.2196/jmir.1596](https://doi.org/10.2196/jmir.1596).
- Heather, A., Chinnah, T., & Devaraj, V. (2019). The use of virtual and augmented reality in anatomy teaching [version 1]. *MedEdPublish*, 8, 77. doi: [10.15694/mep.2019.000077.1](https://doi.org/10.15694/mep.2019.000077.1).
- Jaffar, A. A. (2012). YouTube: An emerging tool in anatomy education. *Anatomical Sciences Education*, 5(3), 158–164. doi: [10.1002/ase.1268](https://doi.org/10.1002/ase.1268).
- Johnson, S. N. (2019). Cognitive processes in undergraduate anatomy and physiology courses (Order No. 27663833). ProQuest Dissertations and Theses Global. (2343285338). Available from: <http://ezproxy.um.edu.my:2048/login?url=https://www.proquest.com/dissertations-theses/cognitive-processes-undergraduate-anatomy/docview/2343285338/se-2>

- Kotzé, S. H., Driescher, N. D., & Mole, C. G. (2013). The translucent cadaver: A follow-up study to gauge the efficacy of implementing changes suggested by students. *Anatomical Sciences Education*, 6(6), 433–439. doi: [10.1002/ase.1365](https://doi.org/10.1002/ase.1365).
- Kowalczyk, K. A., & Majewski, A. (2021). Analysis of surgical errors associated with anatomical variations clinically relevant in general surgery. Review of the literature. *Translational Research in Anatomy*, 23, 100107. doi: [10.1016/j.tria.2020.100107](https://doi.org/10.1016/j.tria.2020.100107).
- Kwon, K., Chung, M. S., Park, J. S., Shin, B. S., & Chung, B. S. (2017). Improved software to browse the serial medical images for learning. *Journal of Korean Medical Science*, 32(7), 1195–1201. doi: [10.3346/jkms.2017.32.7.1195](https://doi.org/10.3346/jkms.2017.32.7.1195).
- Lacey, K., & Wall, J. G. (2021). Video-based learning to enhance teaching of practical microbiology. *FEMS Microbiology Letters*, 368(2), fnaa203. doi: [10.1093/femsle/fnaa203](https://doi.org/10.1093/femsle/fnaa203).
- Leveritt, S., McKnight, G., Edwards, K., Pratten, M., & Merrick, D. (2016). What anatomy is clinically useful and when should we be teaching it?. *Anatomical Sciences Education*, 9(5), 468–475. doi: [10.1002/ase.1596](https://doi.org/10.1002/ase.1596).
- Li, Q., Ran, X., Zhang, S., Tan, L., & Qiu, M. (2014). A digital interactive human brain atlas based on Chinese visible human datasets for anatomy teaching. *The Journal of Craniofacial Surgery*, 25(1), 303–307. doi: [10.1097/SCS.0b013e3182a4c54a](https://doi.org/10.1097/SCS.0b013e3182a4c54a).
- McNulty, J. A., Sonntag, B., & Sincore, J. M. (2009). Evaluation of computer-aided instruction in a gross anatomy course: A six-year study. *Anatomical Sciences Education*, 2(1), 2–8. doi: [10.1002/ase.66](https://doi.org/10.1002/ase.66).
- Mehrpour, S. R., Aghamirsalim, M., Motamedi, S. M., Ardeshtari Larijani, F., & Sorbi, R. (2013). A supplemental video teaching tool enhances splinting skills. *Clinical Orthopaedics and Related Research*, 471(2), 649–654. doi: [10.1007/s11999-012-2638-3](https://doi.org/10.1007/s11999-012-2638-3).
- Moro, C., Birt, J., Stromberga, Z., Phelps, C., Clark, J., Glasziou, P., & Scott, A. M. (2021). Virtual and augmented reality enhancements to medical and science student physiology and anatomy test performance: A systematic review and meta-analysis. *Anatomical Sciences Education*, 14(3), 368–376. doi: [10.1002/ase.2049](https://doi.org/10.1002/ase.2049).
- Moscova, M., Bryce, D. A., Sindhusake, D., & Young, N. (2015). Integration of medical imaging including ultrasound into a new clinical anatomy curriculum. *Anatomical Sciences Education*, 8(3), 205–220. doi: [10.1002/ase.1481](https://doi.org/10.1002/ase.1481).
- Nance, E. T., Lanning, S. K., & Gunsolley, J. C. (2009). Dental anatomy carving computer-assisted instruction program: An assessment of student performance and perceptions. *Journal of Dental Education*, 73(8), 972–979.
- Patel, S. (2009). Anatomy: Too much too soon at medical school. *Clinical Anatomy (New York, N.Y.)*, 22(2), 287–289. doi: [10.1002/ca.20731](https://doi.org/10.1002/ca.20731).
- Pawlina, W., & Lachman, N. (2004). Dissection in learning and teaching gross anatomy: Rebuttal to McLachlan. *Anatomical Record. Part B, New Anatomist*, 281(1), 9–11. doi: [10.1002/ar.b.20038](https://doi.org/10.1002/ar.b.20038).
- Poon, C., Stevens, S. M., Golub, J. S., Pensak, M. L., & Samy, R. N. (2017). Pilot study evaluating the impact of otology surgery videos on otolaryngology resident education. *Otology and Neurotology : Official Publication of the American Otological Society, American Neurotology Society [and] European Academy of Otology and Neurotology*, 38(3), 423–428. doi: [10.1097/MAO.0000000000001303](https://doi.org/10.1097/MAO.0000000000001303).
- Potu, B. K., Atwa, H., Nasr El-Din, W. A., Othman, M. A., Sarwani, N. A., Fatima, A., . . . Fadel, R. A. (2022). Learning anatomy before and during COVID-19 pandemic: Students' perceptions and exam performance. *Morphologie: bulletin de l'Association des anatomistes*, 106(354), 188–194. doi: [10.1016/j.morpho.2021.07.003](https://doi.org/10.1016/j.morpho.2021.07.003).
- Saxena, V., Natarajan, P., O'Sullivan, P. S., & Jain, S. (2008). Effect of the use of instructional anatomy videos on student performance. *Anatomical Sciences Education*, 1(4), 159–165. doi: [10.1002/ase.38](https://doi.org/10.1002/ase.38).
- Sbayeh, A., Qaedi Choo, M. A., Quane, K. A., Finucane, P., McGrath, D., O'Flynn, S., . . . O'Tuathaigh, C. M. P. (2016). Relevance of anatomy to medical education and clinical practice: Perspectives of medical students, clinicians, and educators. *Perspectives on Medical Education*, 5(6), 338–346. doi: [10.1007/s40037-016-0310-4](https://doi.org/10.1007/s40037-016-0310-4).

-
- Shin, D. S., Chung, M. S., Park, J. S., Park, H. S., Lee, S., Moon, Y. L., & Jang, H. G. (2012). Portable document format file showing the surface models of cadaver whole body. *Journal of Korean Medical Science*, 27(8), 849–856. doi: [10.3346/jkms.2012.27.8.849](https://doi.org/10.3346/jkms.2012.27.8.849).
- Singh, V., & Kharb, P. (2013). A paradigm shift from teaching to learning gross anatomy: meta-analysis of implications for instructional methods. *Journal of The Anatomical Society of India*, 62, 84–89. doi: [10.1016/S0003-2778\(13\)80019-6](https://doi.org/10.1016/S0003-2778(13)80019-6).
- Singh, R., Shane Tubbs, R., Gupta, K., Singh, M., Jones, D. G., & Kumar, R. (2015). Is the decline of human anatomy hazardous to medical education/profession?– A review. *Surg Radiol Anat*, 37(10), 1257–1265. doi: [10.1007/s00276-015-1507-7](https://doi.org/10.1007/s00276-015-1507-7).
- Singh, R., Yadav, N., Pandey, M., & Jones, D. G. (2022). Is inadequate anatomical knowledge on the part of physicians hazardous for successful clinical practice?. *Surg Radiol Anat*, 44(1), 83–92. doi: [10.1007/s00276-021-02875-7](https://doi.org/10.1007/s00276-021-02875-7).
- Smith, C. F., Freeman, S. K., Heylings, D., Finn, G. M., & Davies, D. C. (2022). Anatomy education for medical students in the United Kingdom and republic of Ireland in 2019: A 20-year follow-up. *Anatomical Sciences Education*, 15(6), 993–1006. doi: [10.1002/ase.2126](https://doi.org/10.1002/ase.2126).
- Stirling, A., & Birt, J. (2014). An enriched multimedia eBook application to facilitate learning of anatomy. *Anatomical Sciences Education*, 7(1), 19–27. doi: [10.1002/ase.1373](https://doi.org/10.1002/ase.1373).
- Sutkin, G., Littleton, E. B., & Kanter, S. L. (2015). How surgical mentors teach: A classification of in vivo teaching behaviors part 1: Verbal teaching guidance. *Journal of Surgical Education*, 72(2), 243–250. doi: [10.1016/j.jsurg.2014.10.003](https://doi.org/10.1016/j.jsurg.2014.10.003).
- Swamy, M., & Searle, R. F. (2012). Anatomy teaching with portable ultrasound to medical students. *BMC Medical Education*, 12, 99. doi: [10.1186/1472-6920-12-99](https://doi.org/10.1186/1472-6920-12-99).
- Talip, S. B., Mohd Ismail, Z. I., & Hadie, S. N. H. (2021). Investigating the benefits of integrated anatomy instruction: A cognitive load theory perspective. *Education in Medicine Journal*, 13(3), 1–14. doi: [10.21315/eimj2021.13.3.1](https://doi.org/10.21315/eimj2021.13.3.1).
- Tworek, J. K., Jamniczky, H. A., Jacob, C., Hallgrímsson, B., & Wright, B. (2013). The LINDSAY virtual human project: An immersive approach to anatomy and physiology. *Anatomical Sciences Education*, 6(1), 19–28. doi: [10.1002/ase.1301](https://doi.org/10.1002/ase.1301).
- Yammine, K. (2014). The current status of anatomy knowledge: Where are we now? Where do we need to go and how do we get there?. *Teaching and Learning in Medicine*, 26(2), 184–188. doi: [10.1080/10401334.2014.883985](https://doi.org/10.1080/10401334.2014.883985).
- Yan, J., Ding, X., Xiong, L., Liu, E., Zhang, Y., Luan, Y., . . . Zhang, W. (2018). Team-based learning: Assessing the impact on anatomy teaching in people's Republic of China. *Advances in Medical Education and Practice*, 9, 589–594. doi: [10.2147/AMEP.S169949](https://doi.org/10.2147/AMEP.S169949).
- Zargaran, A., Turki, M. A., Bhaskar, J., Spiers, H. V. M., & Zargaran, D. (2020). The role of technology in anatomy teaching: Striking the right balance. *Advances in Medical Education and Practice*, 11, 259–266. doi: [10.2147/AMEP.S240150](https://doi.org/10.2147/AMEP.S240150).

Corresponding author

Pamela David can be contacted at: rosiepamela@um.edu.my

For instructions on how to order reprints of this article, please visit our website:

www.emeraldgrouppublishing.com/licensing/reprints.htm

Or contact us for further details: permissions@emeraldinsight.com